

Figure 4.32: Adjusted ellipses and lumen centers before rows(1,3,5) and after rows(2,4,6) rotation suppression

rotation suppression.

Figure 4.38 shows the Δd distance distribution for 30 patients. We must emphasize, that the distances Δd should not be equal to zero, since we have only applied two rigid transformations, rotation and translation. We have still not eliminated the catheter obliquity and the vessel radial deformation due to the blood pressure, therefore the deformation they induce still remains. It is to consider that the decrement from $\Delta d \approx (0.6 \pm 0.3) \text{ mm}$ or $(15 \pm 8 \text{ pixels})$ before, to $\Delta d \approx (0.3 \pm 0.1) \text{ mm}$ or $(8 \pm 3 \text{ pixels})$ after rotation suppression, is an acceptable result. Finally in order to illustrate the vessel wall appearance before and after rotation suppression we visualize in Fig. 4.39 two orthogonal cut, before (first and third row) and after (second and fourth row) rotation suppression. We can see that the pulsatile deformation produced by the heart dynamics has been eliminated, such as is evidenced in Fig. 4.40, where the

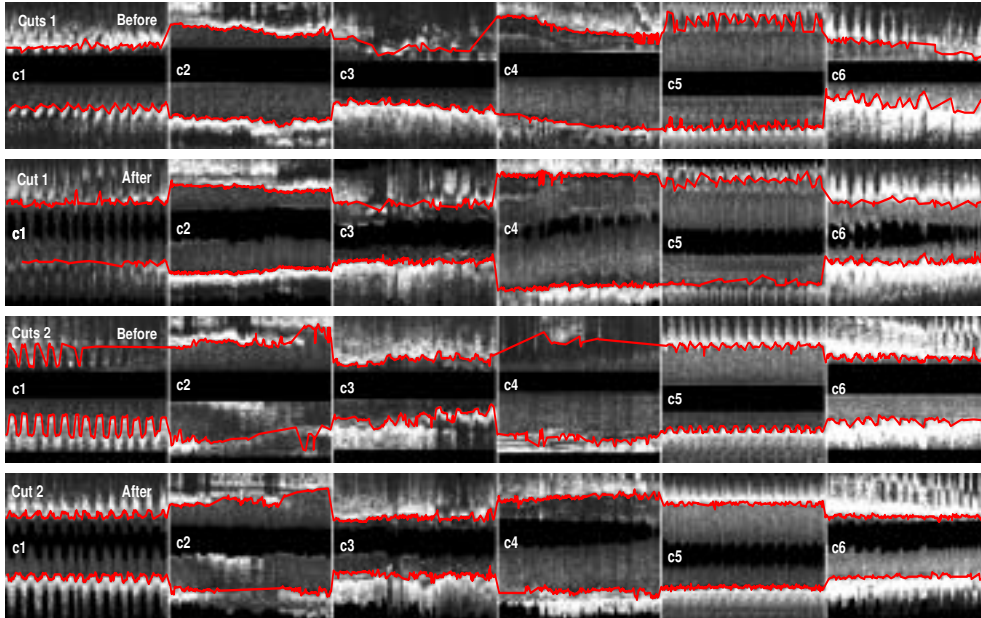


Figure 4.33: Longitudinal cuts $C1$ before (rows (1 and 3)) and after (rows (2 and 4)) rotation suppression.

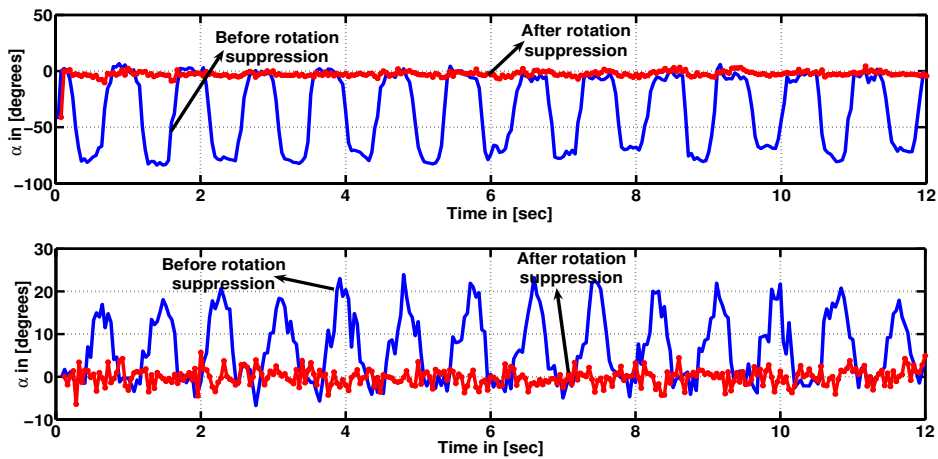


Figure 4.34: Rotation profiles from 2 patients before and after rotation suppression

rotation profile before (blue line) and after (red line) rotation suppression is given. The abrupt changes observed in rotation profile after rotation suppression are due to singularities occurred when the catheter eccentricity is approximately zero (See Fig.

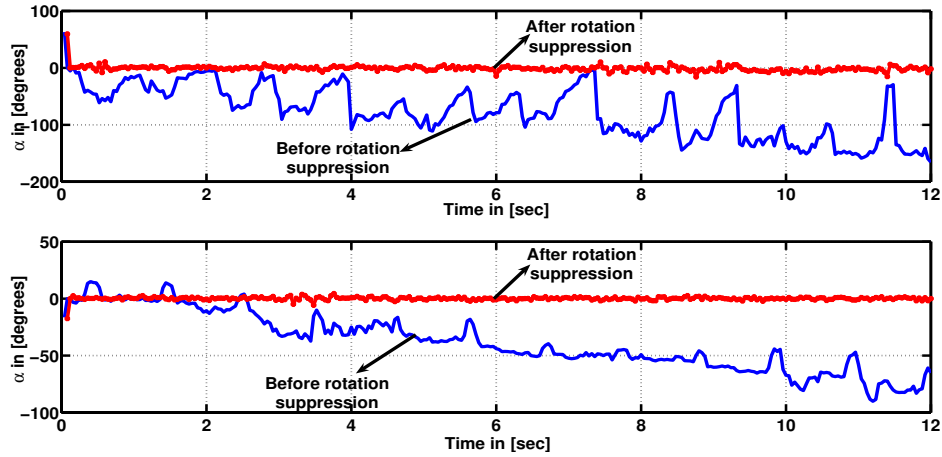


Figure 4.35: Rotation profiles from 2 patients before and after rotation suppression

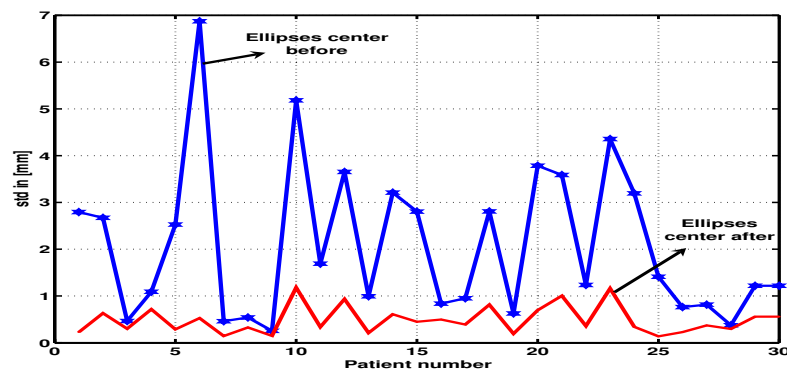


Figure 4.36: Ellipses centers standard deviation from 30 patients before (blue) and after (red) rotation suppression.

4.22).

4.5 Healthy and Pathological Rotations Profiles.

Our experiments focus on assessment of the rotation suppression and illustration of a possible application to pathology diagnosis. We studied the local rotation profile in order to study differences between healthy and pathological vessel segments. The comparative analysis is based on the period and the amplitude of the profile. For our basic comparative analysis we considered a healthy segment and 29 pathological ones including soft plaque, hard plaque and mixed plaque. The rotation profiles $\alpha(t)$

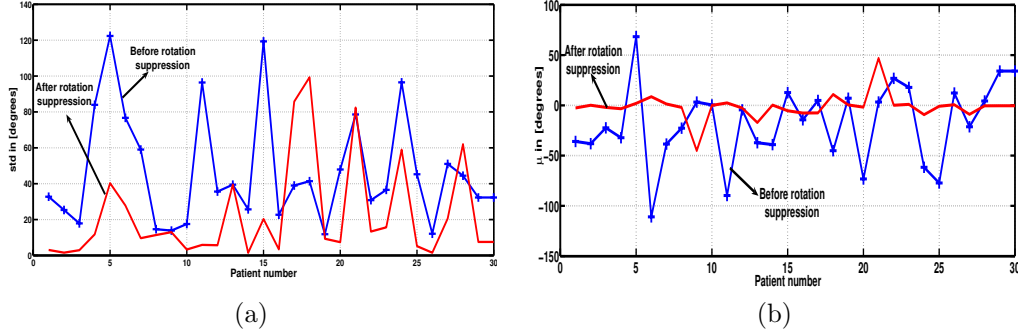


Figure 4.37: Standard deviation σ (a) and average μ (b) of the rotation angle, from 30 patients before and after rotation suppression.

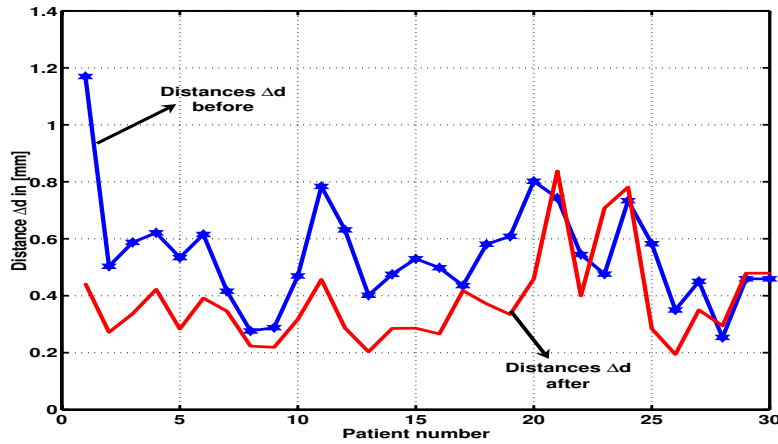


Figure 4.38: Distance to linear fitting before and after rotation suppression.

obtained from 300 frames (≈ 12 sec) are shown in Fig.4.41. The patients were ordered from major to minor lumen area. We have selected a healthy vessel segment labelled as (P1) in Fig.4.41. P1 presents a regular periodic behavior with an oscillation amplitude of ($\mu \approx 79$) degrees and standard deviation of $\sigma \approx 33$ degrees, the period coincides with the heart beat rate. Soft plaque patients (first and second row except P1) in Fig.4.41, still follows a periodic pattern synchronized with the heart beat, its mean amplitude ($\mu \approx 76$) degrees and standard deviation of $\sigma \approx 11$ degrees, depending on the severity of the lesion. Hard plaque (third and fourth row) results in a suppression of vessel oscillation. Finally, the mixed plaque (fifth and sixth row) profile is the most irregular one lacking of any visual periodicity. Figure 4.42 displays each one of 30 cross sectional IVUS images.

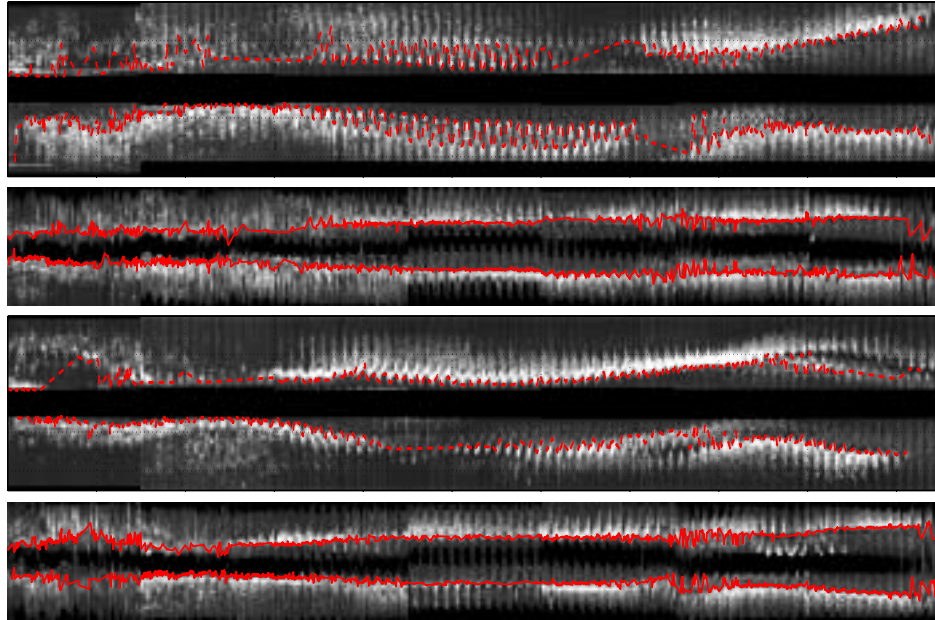


Figure 4.39: Longitudinal cut before (rows 1 and 3) and after (rows 2 and 4) rotation suppression

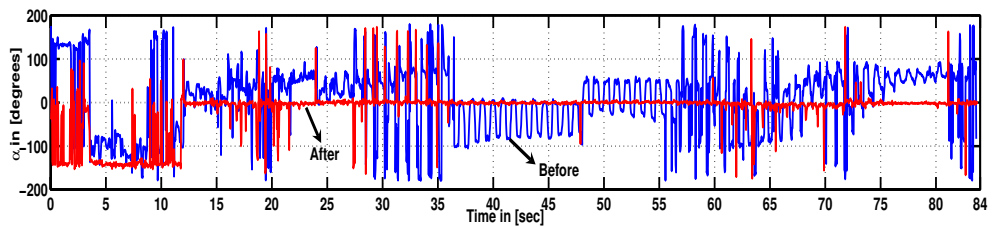


Figure 4.40: Rotation profile before and after rotation suppression, corresponding to patient from figure 4.39

Figure 4.43 shows the lumen area of 30 patients versus standard deviation of rotation profile.

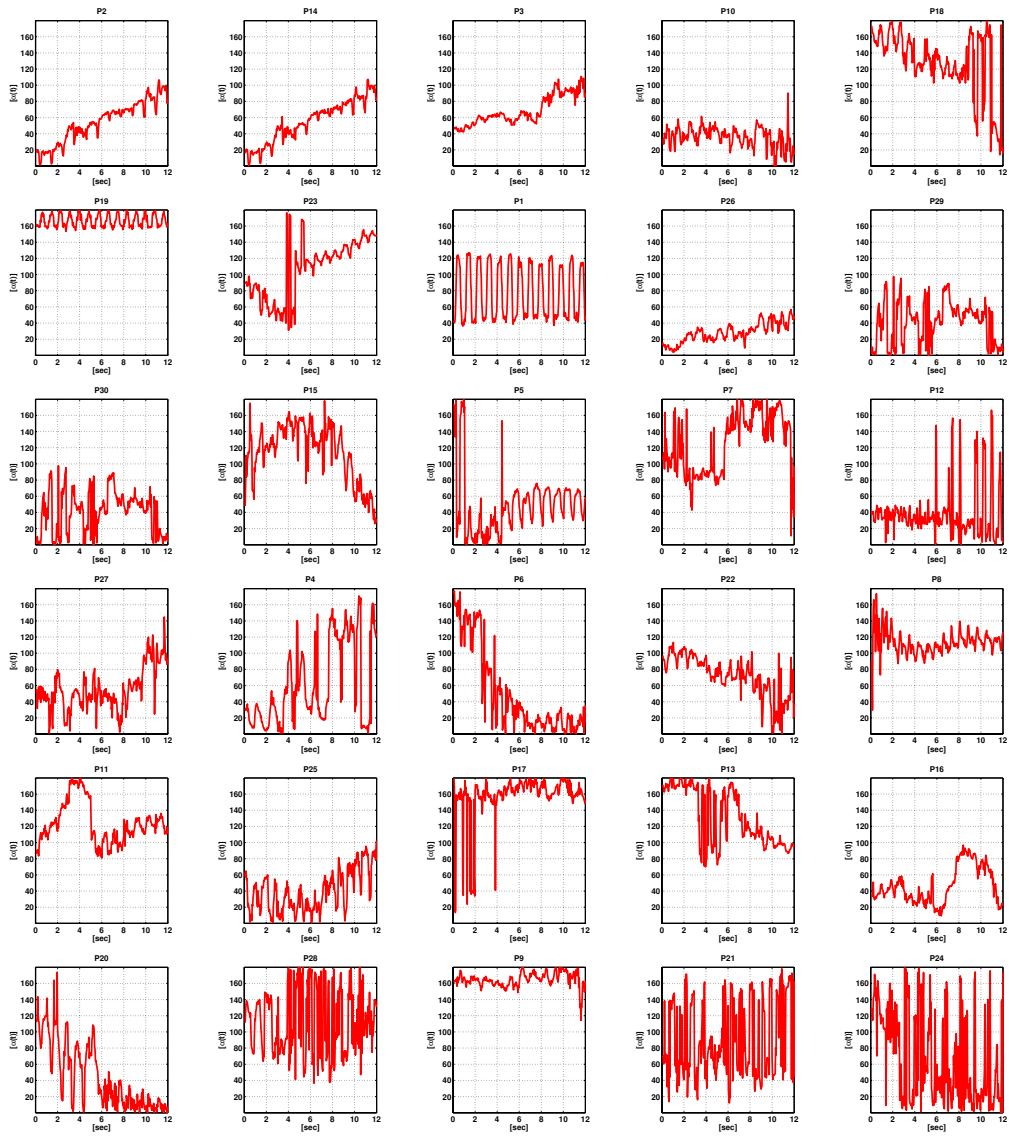


Figure 4.41: Rotation profiles $\alpha(t)$ in degrees from 30 patient, ordered from major to minor lumen area

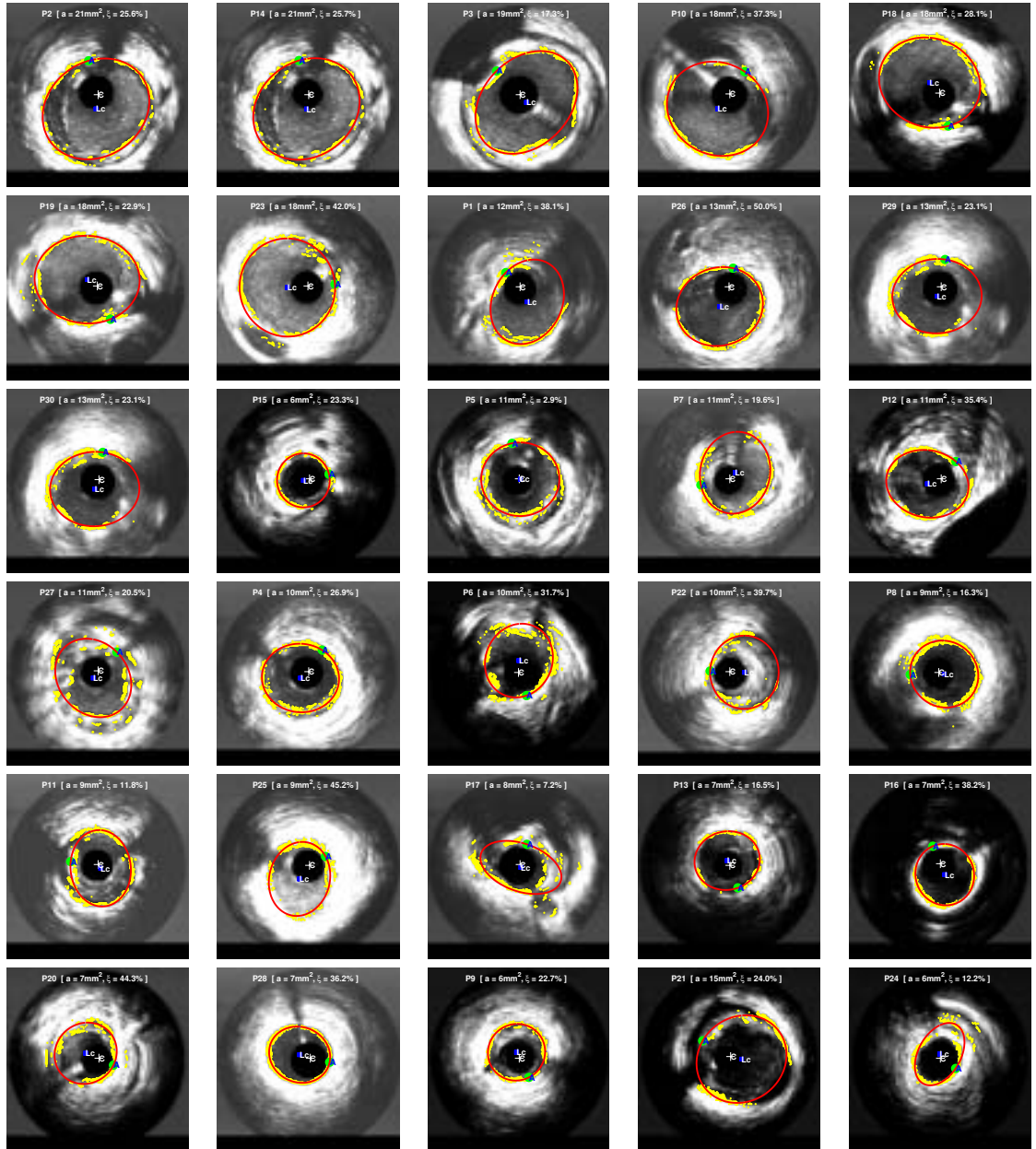


Figure 4.42: Elliptical adjust of vessel wall average from 300 frames corresponding to 30 patients, ordered from major to minor area. L_c is lumen center, C catheter center and A ellipse point located at minimal distance to the catheter, a is the lumen area and ξ is the catheter eccentricity.

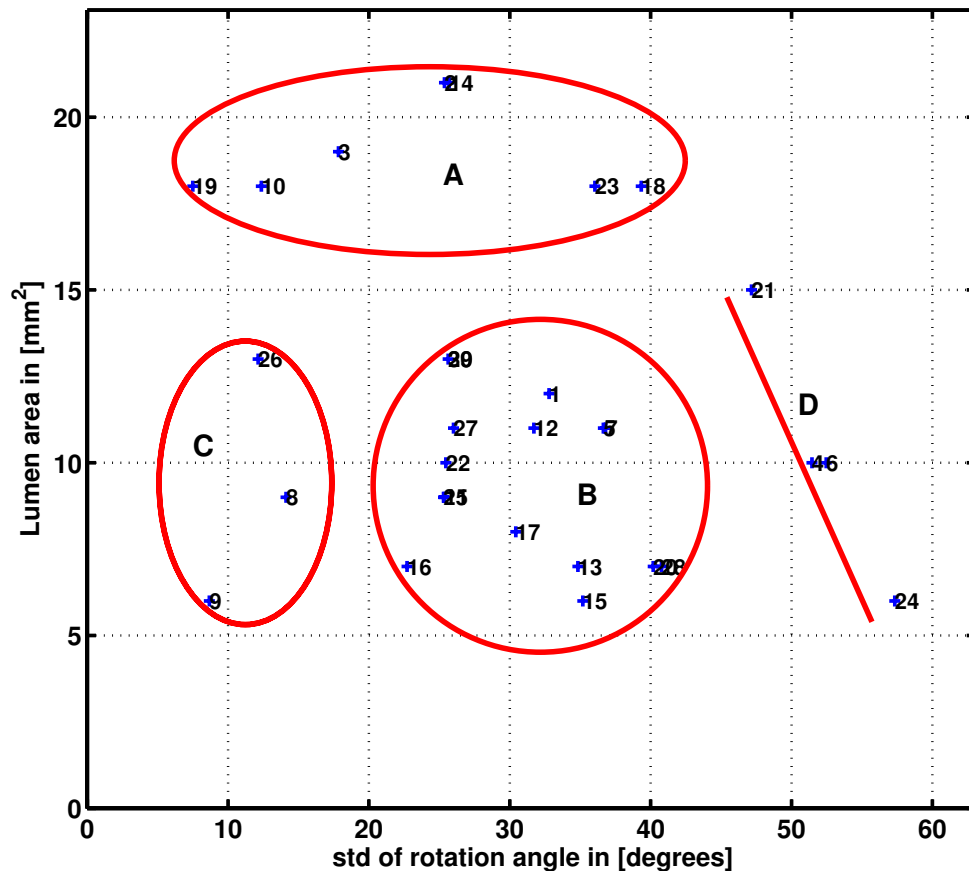


Figure 4.43: Lumen area versus standard deviation of rotation angle α . Labels: A is soft plaque, B hard plaque, C and D mixture plaque